



# Cone Beam CT — Anatomic Assessment and Legal Issues: The New Standards of Care

ARTHUR CURLEY, JD, AND DAVID C. HATCHER, DDS, MSC

**ABSTRACT** Until the recent introduction of cone beam computed tomography scanners, standard 2-D imaging provided a moderate contribution to overall treatment planning when considering the diagnostic potential, costs of study, and risks to the patient. Cone beam computed tomography-dedicated maxillofacial imaging scanners provide broader imaging tools for anatomic assessment and have become widely available. This article discusses the uses and benefits of 3-D imaging, as well as the impact on the standard of care.

## AUTHORS

**Arthur Curley, JD**, is assistant professor, dental jurisprudence, Arthur A. Dugoni School of Dentistry, and president and senior trial counsel with Bradley, Curley, Asiano, Barrabee & Gale PC in Larkspur, Calif.

**David C. Hatcher, DDS, MSC, MRCD**, is a clinical professor, University of Southern Nevada, adjunct associate clinical professor, Arthur A. Dugoni School of Dentistry, and in private practice at Diagnostic Digital Imaging, in Sacramento.

**M**any phases of patient care involve imaging to assist with diagnosis, treatment planning, risk assessment, and treatment. Techniques employing X-rays, visible light, ultrasound, lasers, and magnetic fields have been used in medicine and dentistry to create images. All forms of imaging require a coupled system of emitters and sensors. For example, a cephalometric image is produced using an X-ray emitter and film sensor. Imaging systems can be categorized in many different ways based upon emitter or output type (examples; film-based, digital, 2-D and 3-D images).

The resultant images can be used to evaluate the anatomy of interest, including surface and subsurface. The ultimate quest of all forms of imaging is to reveal the anatomic truth; that is, to portray the anatomy as it exists in nature. Thoughtful

clinical application of image acquisition requires matching the uses and limitations of the available imaging choices to achieve the desired diagnostic information (imaging goal) while keeping the risks and costs to the patient as low as possible.

Imaging data must provide a benefit at an acceptable cost and risk. Two-dimensional representation of 3-D anatomies creates images that have poor spatial accuracy, are static in space and time, and contain information voids. These 2-D measurements have propagated legacy databases of inaccurate morphometric measurements.<sup>1</sup>

Current development in imaging technology for dentistry includes digital imaging and improved sensor technology. Multidimensional anatomical reconstruction can be performed through software applications. The ultimate reward of technological imaging advancements is the 3-D representations (digital vol-

ume) of anatomy as it exists in nature (anatomic truth).<sup>2</sup> Analysis of the accurate digital volume can provide clinically relevant spatial information or data.

Visualization and analysis of 3-D information can benefit a dental practice by providing data that will improve diagnosis, risk assessment, treatment outcome, and treatment efficiency, and reduce treatment complications. This article discusses the uses and benefits of 3-D imaging (cone beam CT, CBCT) for diagnosis, treatment planning and the legal issues affecting the standard of care, as well as offering risk management tips and use guidance.

### The Standard of Care

The term “standard of care” is generally defined as what a reasonable and prudent health care provider would do or should have done. The law requires that a dentist meet or exceed the standard of care. Failure to do so is considered professional negligence, commonly called malpractice.

Specifically, California law states that a dentist is negligent if he/she fails to use that level of skill, knowledge, and care in diagnosis and treatment that other reasonably careful dentists would use in the same or similar circumstances. This level of skill, knowledge, and care is sometimes referred to as “the standard of care.”<sup>3</sup> “Similar circumstances” includes the requirement of staying current with improvements in, and alternatives to, traditional care where the benefits and risks vary, depending upon the treatment plan chosen.

The California Dental Practice Act mandates that a dentist, and all other licensed staff, adhere to the standard of care. Any licentiate may have his/her license revoked or suspended, or be reprimanded or be placed on probation by the board for unprofessional conduct, or incompetence, or gross negli-

gence, or repeated acts of negligence in his or her profession.<sup>4</sup> In a malpractice suit, the patient must prove that the defendant was negligent for failure to meet the standard of care and that such failure caused an avoidable injury, for which a judge or jury can award monetary damages. At trial, experts for each side offer testimony on the issue of the standard of care, causation, and injury.

Typically, a jury will determine, based upon the records and testimony of the parties and expert witnesses, whether

**THE TYPE OF ALTERNATE diagnostic and treatment options to be discussed cannot be determined by the patient's apparent financial ability to pay.**

or not the defendant failed to meet the standard of care, based primarily upon witness credibility.<sup>5</sup> The jury is told “You should examine the reasons given for each opinion and the facts or other matters that each witness relied on.”<sup>6</sup> Imaging, particularly 3-D, can be very persuasive to juries. While experts may use their own experience and cite authoritative texts, legally, a technology becomes admissible evidence of a standard of care when it meets a three-part test known as Frye/Daubet: 1) sound scientific basis; 2) disseminated via peer-reviewed literature; and 3) (if a product) approved by the appropriate regulatory agency, such as the FDA.<sup>7,8</sup> Accordingly, as discussed herein, CBCT meets the legal definition of a standard of care for imaging,

### Options and Patient Information

Practically speaking, the traditional standard of care involved delivery of reasonably accurate and up-to-date diagnosis, treatment recommendation(s), treatment performance(s), and follow-up care. As discussed herein, another standard of care involves giving the patient diagnostic and treatment options, discussing and documenting the relative risks and benefits of each.<sup>9</sup> Examples would be implants versus bridges; veneers versus orthodontics; amalgam versus composites; and most importantly, CBCT versus traditional 2-D imaging.

The type of alternate diagnostic and treatment options to be discussed cannot be determined by the patient's apparent financial ability to pay. Rather, the doctor must give ideal (regardless of cost) treatment plans, as well as less-than-ideal options to treat a condition, and then allow the patient to make an informed choice.

The prudent practitioner should then document the patient's decision, and, if a less-than-ideal plan is chosen, obtain and document the informed refusal.<sup>10</sup> That is, document that the patient was given the options, risks, benefits, and alternatives to each and told the risks of the decision made. Example: A patient chooses a removable partial denture over an implant due to insurance coverage limitations.

The standard of care is dynamic, constantly evolving, and at an ever-increasing rate. Accordingly, it has become even more important for a careful practitioner to stay current of the new developments in dental care, related risk management techniques, and documentation protocols in order to understand and comply with the legal standard of care.

### Evolving Standards

Dentistry is perhaps one of the most technology driven areas of health care delivery. Its roots go back to the basics of

removal of decayed teeth and attempts at replacements, such as George Washington's famous wooden dentures. (In fact made of animal and human teeth).<sup>11</sup> Treatment of dental pathology has evolved with improved mechanical systems for decay removal, extractions, restorations, tooth alignment, root canal therapy, and replacement of teeth. Before the advent of dental X-rays, treatment planning was limited to clinical observations and therefore had numerous unavoidable risks.

A risk is complication of treatment that cannot be avoided with reasonable skill, care, or technology. Therefore, the law mandates that patients have to be informed of the various treatment options and attendant risks so they could make an informed decision.<sup>12</sup> Sound risk management requires documenting such discussions by obtaining written informed consent. Such documentation provides a strong defense to claims of dental malpractice from patients experiencing treatment complications that were unavoidable.

The advent of dental X-rays dramatically changed dentistry and the standard of care. X-rays facilitate diagnosis, treatment planning, and improved outcomes while reducing risks. However, due to the limitations of traditional 2-D imaging, many risks, such as nerve injuries with extractions, could not be eliminated. As options for dental care expanded, so did the attendant risks, such as nerve injury from the placement of a dental implant. Such complications were considered risks that were not completely avoidable, despite meeting the standard of care.

However, with the development and ready availability of CBCT scanners, practitioners can now see and appreciate anatomy in 3-D, almost approaching in vivo. That additional information contributes so substantially to diagnosis and treatment planning that many risks can now be avoided.

### Informed Refusal

Traditionally, practitioners developed treatment plans based upon need and ability to pay. Due to the limits of dental insurance coverage, new and evolving dental technologies, such as composites, retainer orthodontics, and implants were not covered by insurance and therefore not recommended or sometimes even discussed. However, the patient's legal right to choose mandates a discussion of all reasonable options, regardless of payment. Failure to offer noncovered op-

THE PATIENT'S  
legal right to  
choose mandates  
a discussion  
of all reasonable  
options, regardless  
of payment.

tions is substandard care. In other words, the doctor has an obligation to advise the patient of the ideal treatments, not just the ones the patient can afford, and to also advise of the risks and benefits of the alternatives or those plans.

Further, if a patient chooses a less-than-ideal treatment plan due to funding issues, the comparative risks must be explained and that discussion documented. Today, a doctor can be liable for problems experienced by a patient who either was not told of potential alternative treatments or was not told the risks of refusing a recommended treatment.<sup>13</sup> This has become known as the doctrine of informed refusal, now formalized as a California Civil Jury instruction 534-5.<sup>14</sup> Therefore, as will be discussed below, the potential for

risk reduction or elimination with CBCT is such that failure to offer it in many cases may be considered substandard care.<sup>15</sup>

### Cone Beam CT (CBCT)

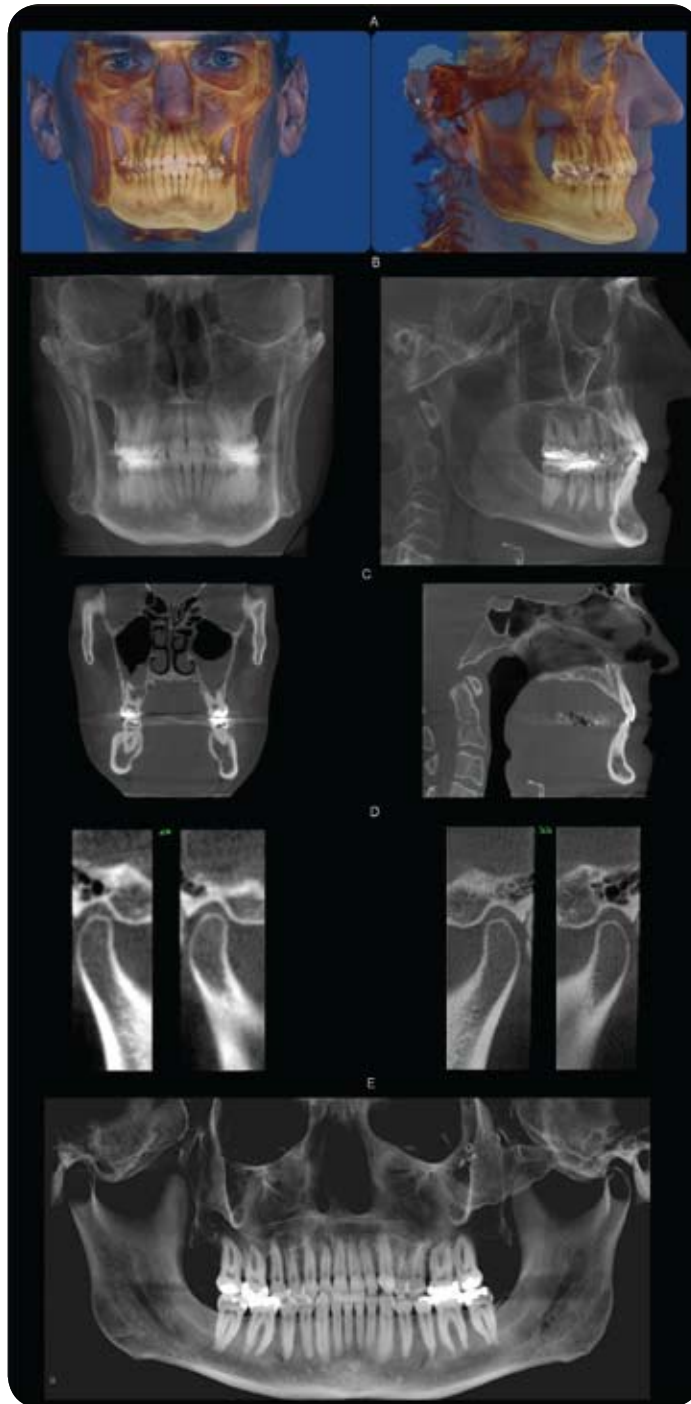
CBCT uses a low milli-Amperage cone-shaped X-ray beam that can be shaped to approximate the area of interest. The X-ray emitter and sensor rotate 360 degrees around the head creating a sequence of images (raw data) that are reconstructed into a voxel (digital) volume for visualization and analysis. Two-dimensional digital images are comprised of subunits called picture elements (pixels) while 3-D digital images are comprised of subunits called volume elements (voxels). Pixels and voxels possess attributes of size, location, and a grayscale value. The current generation of CBCT scanners produce isotropic voxels (x, y, and z dimensions are equal) that range from 0.1 to 0.4 mm with a grayscale value between 12 bits (4,096 shades of gray) and 14 bits (16,384 shades of gray). Each voxel in a 3-D digital image is assigned a grayscale value that represents the averaged attenuation value of all of the structures contained within that volume.

### Visualization

A significant amount of anatomic information is contained within a voxel volume and this information can be retrieved, analyzed, and viewed at a computer workstation using visualization and analysis software. The computer monitor is a 2-D eight-bit display (256 gray levels) used to display 3-D 12- or 14-bit image data. In order to view 12- or 14-bit data on an eight-bit monitor, a software technique of "windowing" allows for the visualization of the entire 4,096 or 16,384 shades of gray, eight bits at a time.

Visualization software allows the entire volume to be rotated and viewed

**FIGURES 1A-E.** This figure illustrates various visualization options. **(A)** Frontal and lateral views of a composite model of the skin and skeleton. The entire 3-D volume is visualized using a volume-rendering technique. Selected tissues can be assigned various opacity levels so that the spatial relationships can be determined. **(B)** Frontal and lateral cephalometric projections are generated from the 3-D volume using parallel rays (orthogonal projection). The head orientation can be perfectly controlled. **(C)** Coronal and sagittal sections can be created and displayed. **(D)** Corrected views of the temporomandibular joints. **(E)** A reconstructed panoramic projection created from the scan volume.



from any point of view. In addition, the software allows for orthogonal (sagittal, axial, or coronal planes), oblique or curved plane slicing or paging through the voxel layers to allow visualization of internal anatomy (**FIGURES 1 AND 2**). Slice thickness can be manipulated directly and in real time. The volume of image data can be viewed using different modes of display, including multiplanar reformatting, shaded surface display, and volume rendering. The highest resolution (best quality) images allow for visualization of small anatomic features. In general, the best quality 3-D images are produced using a protocol that selects for the greatest number of gray levels, smallest voxels, and a high signal and low noise ratio. Patient motion is the greatest contributor to noise in a CBCT scan.

### *Imaging Sessions*

Any imaging session begins with the development of imaging goals that fulfill the clinical objective. Imaging goals allow for the selection of an imaging protocol and creation of an imaging portfolio that best fulfills the clinical objective. Imaging protocol variables include field of view (FOV), voxel size, scan time and milli-Amperage (mA) settings.

Imaging goals fulfill clinical objectives. For example, a clinical goal could be to localize an impacted maxillary cuspid tooth prior to treatment (**FIGURES 2 AND 3**).<sup>16,17</sup> The general imaging goals for impacted teeth include: localize the impacted tooth, localize the adjacent anatomy, and identify pathology.

### *Localization of Impacted Tooth*

It is important to determine the precise location of the crown and the root of an impacted tooth. Accurate location information in all three axis of space may be used to determine surgical

access options, assessing movement, or removal pathways, as well as identify the location of pertinent adjacent anatomy, such as nerve canals and sinus position.

#### Localize Adjacent Anatomy

CBCT can expose the anatomy of interest around an impacted tooth including adjacent teeth, mandibular canal, fossae, sinuses, and alveolar ridge boundaries.

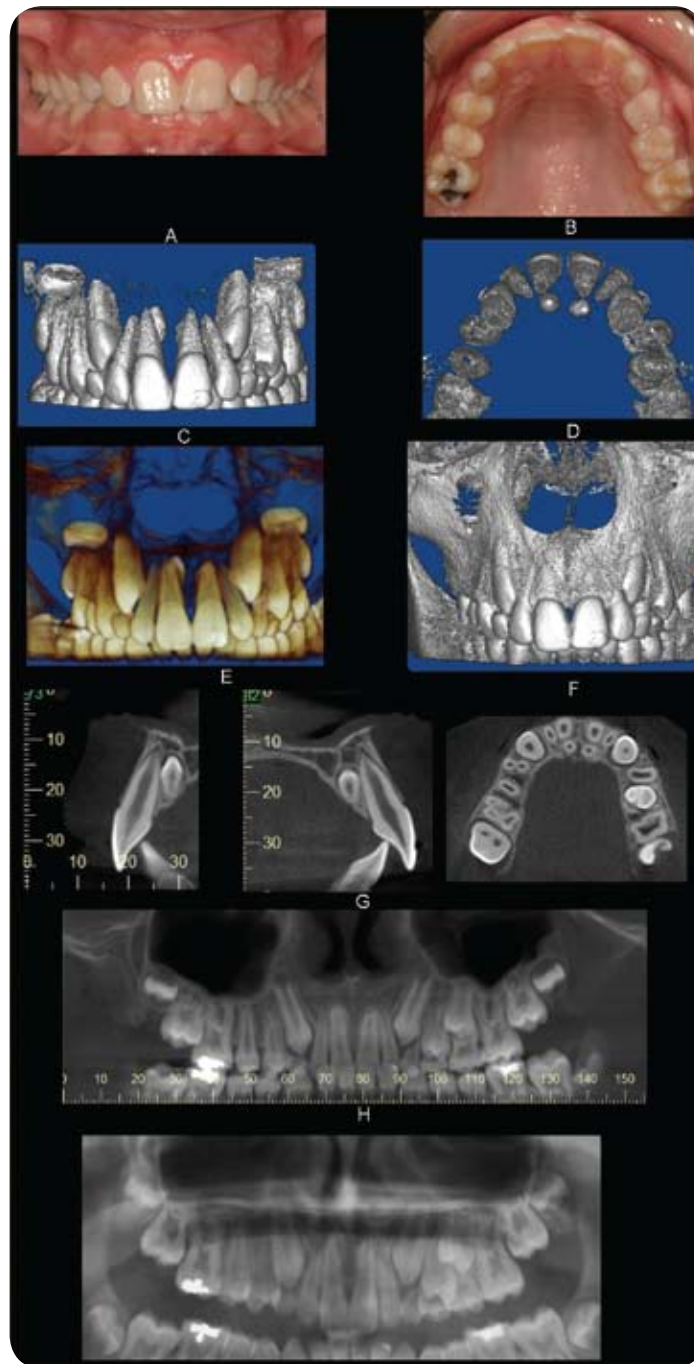
Understanding the location of the adjacent anatomy assists in avoiding surgical trauma and collisions when moving or removing the impacted tooth (FIGURE 4).

#### Identify Pathology

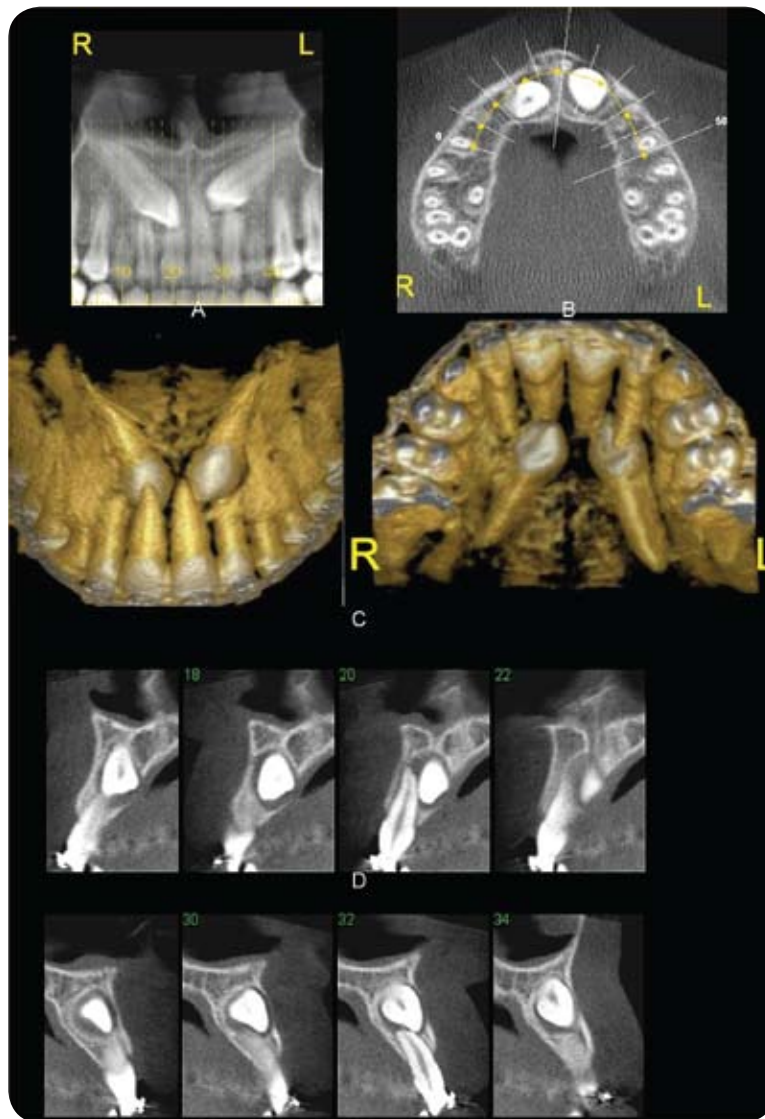
Impacted teeth may be associated with pathology. In some cases, a tooth is impacted because of adjacent pathology, such as a supernumerary tooth or neoplasm (FIGURE 2) that is not visible on standard 2-D imaging. In other cases, pathology can occur adjacent to or secondary to an impacted tooth, such as cysts, tumors, or inflammatory processes. Pathologic findings need to be identified, diagnosed, and managed along with the impacted tooth.

Once a scan has been completed, there are an infinite number of methods available to visualize the image data. An image portfolio, a specific and precise collection of image views and anatomic renderings, is an elegant method to visualize and communicate the imaging goals and findings.

Examples of the potential benefits for achieving the desired imaging objective for the stakeholders (surgeon, orthodontist, and patient) can be seen in the clinical scenario of an impacted maxillary cuspid. The surgeon can better inform patients of a treatment plan and treatment risks, and then plan and perform a minimally invasive surgery with precise placement of traction device because of knowing the location of a



**FIGURES 2A-H.** This figure illustrates various methods that can be used to visualize impacted teeth Nos. 6, 11, and adjacent supernumerary teeth. **(A)** Shaded surface display (SSD) of the anterior region of the maxilla. The SSD threshold was set to show the roots and crowns of the teeth. **(B)** SSD rendering oriented in an axial view to show the supernumerary teeth and the adjacent teeth. **(C)** Volume rendering with the opacity levels set to eliminate bone and soft tissues. **(D)** SSD frontal view with the threshold set to show bone and teeth. **(E)** Cross-sections of the maxilla showing teeth Nos. 8 and 9, along with the two lingually positioned supernumerary teeth. **(F)** Axial section of the maxilla at the level of the supernumerary teeth. **(G)** A reconstructed panoramic projection showing the impacted maxillary cuspids and the adjacent erupted teeth. **(H)** A traditional panoramic projection allowing for visualization of the same anatomy depicted on image H. Note the reduction in clarity and the amount of superimposition on the traditional panoramic projection.



**FIGURES 3A-D.** Impaction localization. A concise image portfolio using various rendering methods that satisfy the imaging goals for impacted teeth. This figure illustrates the 3-D location of the impacted teeth Nos. 6 and 11 and was selected because of the subtle uniqueness differences between the two impacted teeth. **(A)** A reconstructed panoramic projection centering the teeth in the section plane. Images A, B, and D are cross-referenced with each other. The image cross-referencing is communicated with numbers and white lines. **(B)** An axial section of the maxilla displaying the crowns of teeth Nos. 6 and 11. **(C)** Volume rendering the maxilla viewed from anterior and posterior directions. These images show the relative location of the crowns and roots of all of the anterior teeth. **(D)** Cross-sectional views of tooth No. 6 (top panel) and No. 11 (bottom panel). The crown to tooth No. 6 was lingual to the root of tooth No. 8 and contacting the root apex of tooth No. 7. The crown of tooth No. 11 was labial to the root apex of tooth No. 10. The root apex of tooth No. 10 showed some external resorption. (Case courtesy of Amnon Leitner, Israel.) The traction mechanics to mobilize tooth No. 6 into place is likely to be different than the traction mechanics require for tooth No. 11. Understanding the spatial relationships between teeth Nos. 6 and 11, and the adjacent teeth allows for precise planning, risk assessment, and implementation of a treatment strategy that can conserve treatment time and avoid further damage to the erupted teeth.

vital structure, such as nerve, in 3-D.

The orthodontist can design and implement traction mechanics to move teeth into proper alignment without contacting or damaging adjacent teeth. Current technology provides for digital sectioning by fractions of a millimeter (0.12 – 0.50) that can reveal structures, not typically seen in 2-D imaging, such as mesiodens. Three-dimensional imaging can also assist the presentation of the case to the patient and the discussion of the risks, benefits, and alternatives necessary to obtain informed consent.

The patient can be presented with a more clear diagnosis, treatment plan, and therefore obtain a better understanding of risks, benefits, and treatment options.

While 3-D imaging can reduce risks associated with extractions, congenital anatomical associations of vital structures, such as roots and nerves, it can present unavoidable risks.

### Implants

Similar clinical and imaging goals can be derived for presurgical imaging for implants, TMD, and orofacial pain investigations and orthodontics.<sup>18-22</sup> The key stakeholders for implant planning and placement include a restorative dentist, a surgeon, and a patient.

#### Implant Site Assessment Imaging Goals

One current planning routine for the replacement of missing teeth with implants can be called a “crown down” approach where the prosthetic planning precedes implant planning and implant placement (**FIGURE 5**). A CBCT scan, in combination with software modeling, can be used as a virtual planning environment to iterate the ideal placement of the prosthetics, occlusion and associated supporting implants, in a virtual environment.<sup>23-25</sup> For each implant site,

the following anatomic considerations or imaging goals may allow the clinician to determine the best site for the implant and meet the prosthetic goals:

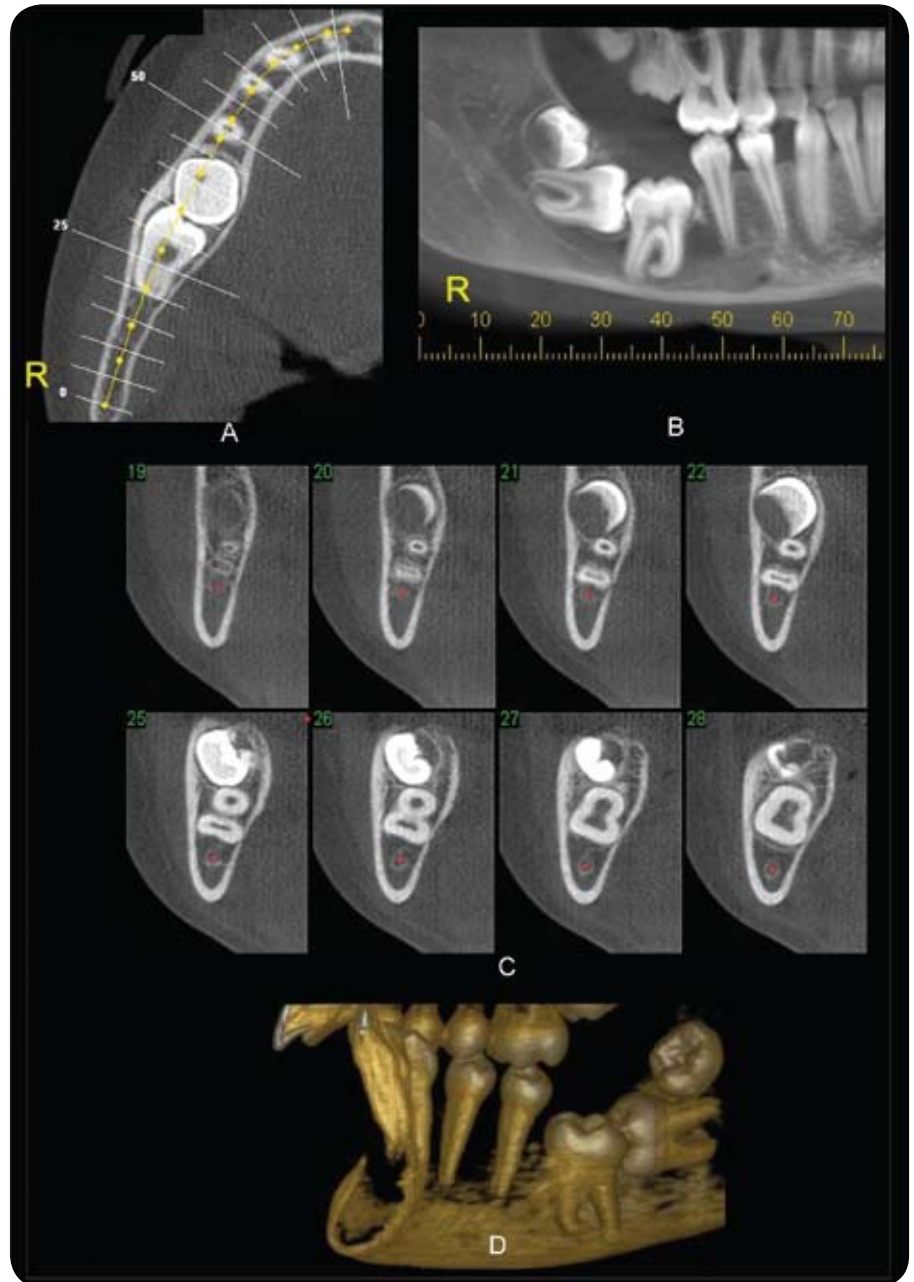
1. Determine bone height and width (bone dimensions) via 3-D CBCT
2. Determine bone quality with comparative density analysis in 3-D
3. Determine the long axis of alveolar bone
4. Identify and localize internal anatomies, such as nerves and sinus cavities
5. Determine jaw boundaries
6. Identify pathology in 3-D scale and scope
7. Transfer of radiographic planning information
8. Communicate radiographic diagnostic and planning information

#### Bone Dimensions

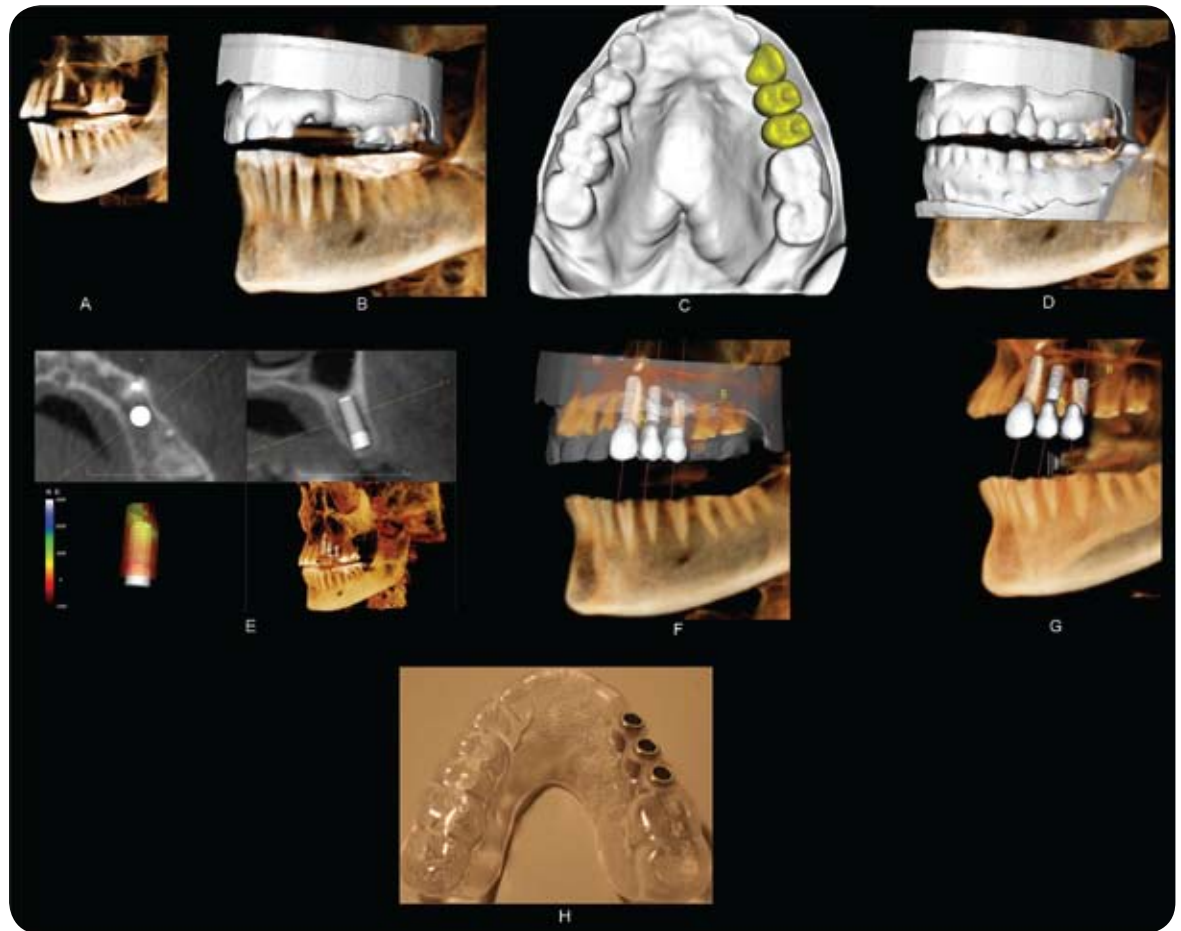
Three-dimensional CBCT presentation of bone height and width allows the clinician to determine how much bone is available in the proposed implant site without having to do enlargement estimates.

#### Bone Quality

Dynamic loading of an implant imparts forces to the adjacent bone. There is an assumption that bone density is directly proportional to the load-bearing capacity of the bone and that implant failure is associated with low bone density.<sup>8</sup> The architecture of the supporting bone is also a factor associated with the functional capacity of these tissues. Dynamic loads received by the implants may strain the supporting bone and induce changes in that bone. Bone requires a certain amount of strain for maintenance, but excessive strain may cause fatigue failure of the trabeculae. A 3-D CBCT can determine bone quality with more accuracy than 2-D imaging.



**FIGURES 4A-C.** Impaction localization. This image portfolio illustrates the clinically relevant story about impacted teeth Nos. 30 and 31. Images A, B and C were cross-referenced with each other: (A) Axial view of teeth Nos. 30 and 31. This image is used to reconstruct the panoramic view (B) and cross-sectional views (C). The localization of teeth Nos. 30 and 31 relative to the adjacent teeth, mandibular canal (marked using red) and the buccal and lingual cortices of the mandible can be determined. Three-D rendering and oriented in space to show the spatial relationships between the teeth (D). This image portfolio can be used to determine treatment options, treatment risks, to communicate appropriate information to the patient and to guide treatment. (Case courtesy of Amnon Leitner.)



**FIGURES 5A-H.** Implant planning sequence. Implant placement involves multiple steps to replace the missing teeth and can be quite complicated and time intensive. This sequence of images demonstrates a workflow efficient method of virtually planning a “crown down” method of implant planning using a CBCT scan to drive the entire process to a guided surgical template. This technique does not require a scan guide. The patient is scanned using a CBCT targeting the proposed implant site (A). In this case, teeth Nos. 20, 21, and 22 are proposed sites for implants (note root tips for teeth Nos. 20 and 22). The upper jaw and teeth are segmented from the CBCT volume creating an interactive model of the region (B). The virtual wax-up is performed (C) to determine the size, form, and location of the clinical crowns for teeth Nos. 20-22. The model of the maxillary teeth can be virtually articulated with a model of the mandibular teeth (D) to iterate the correct prosthetic plan. The location of the replacement crowns is used to determine the best placement of the supporting implants. A manufacturer specific implant form can be selected from a database of implants and virtually placed into the ideal position (E) to best support the planned prosthesis. This method allows optimization of 1) spacing between implants; 2) spacing between implants and adjacent teeth; 3) depth placement of the coronal and apical portions of implant; 4) axial inclination of implant; and 5) buccolingual location of implant within alveolar ridge. In addition, the bone quality assessment and localization of adjacent anatomical structures, such as the maxillary sinus, can be achieved. Images (F) and (G) use a volume-rendering method to show the proposed crowns and supporting implants placed into the CBCT volume. The completed plan can be used to fabricate a surgical guide (H) to aid in accurate placement of the implants. The surgical guide attaches to the adjacent teeth for stability. (Courtesy of Anatomage and InVivo software, San Jose.)

### Long Axis of the Alveolar Bone

Axis orientation describes the angle formed by the vertical long axis of the alveolar-basal bone complex when viewed in cross-section. Information about the axis orientation is important for successful alignment of the implant within the boundaries of

the jaws. Determining the long axis of the alveolar bone allows the clinician to optimize the trajectory of implant placement with the emergence profile and loading characteristics of the implant. Risks such as perforation, dehiscence, and fracture can therefore be avoided with CBCT 3-D imaging.

### Internal Anatomy

The most common internal anatomy to be identified and localized includes the mandibular canal, maxillary sinus, nasal fossa, mental foramen, incisive canal, and adjacent teeth. Identifying these structures aids the clinician in determining the boundaries for implant placement. In con-

trast to extractions, where the anatomical associations are predetermined in nature, the placement of implants requires the practitioner to determine the proximity of vital structures to the implant.

### *Jaw Boundaries*

Imaging can be used to identify the outer boundary of the jaws including impressions into the jaws, such as fossae.

### *Pathology*

Jaw pathology in the proposed implant site or within the maxillofacial regions is important to identify, diagnose, and manage. Abnormalities involving the alveolar ridge include retained root tips, inflammatory processes, cyst, and tumors. In addition, anomalies involving other maxillofacial structures, such as maxillary sinuses and temporomandibular joints may complicate the successful implant process. For example, changes in stress (force/area) directed at poorly adapted TMJs may increase TMJ symptoms. Changes in TMJ stress levels may result from operative manipulations, changes in masticatory abilities, and changes in vertical dimension or maxillomandibular spatial relationships.

### *Transfer of Radiographic Planning Information*

The diagnostic and treatment planning process generates a 3-D “blueprint” consisting of 3-D coordinates for the precise location of each of the planned implants. Surgical guides, radiographic stents, and navigation coordinates are finalized from the 3-D blueprint and can be used at the time of surgery to assist the clinician in transferring this coordinate information to the mouth.<sup>26-28</sup> Because CBCT 3-D can use volumetric analysis to determine ideal implant location, failures of placement can be considered evidence of substandard placement.

### *Communication*

Image data, including the image portfolio, treatment simulations, and CT volume, can be used to inform the stakeholders regarding the diagnosis, treatment plan, treatment options, and associated risks at a level of accuracy unachievable with traditional 2-D imaging.

### *Results*

The introduction of CBCT creates the opportunity for clinicians to acquire the highest quality diagnostic images with an absorbed dose that is comparable to other dental surveys and less than a conventional CT.<sup>29</sup> The diagnostic and risk management processes featured in this article are summarized with the following procedural sequence and associated acronym: ESPIP.

The clinical exam “E” is used to develop clinical objectives and the associated imaging goals. An imaging scan “S” is completed applying a specific imaging protocol and creating an image portfolio that satisfies the imaging goals. The plan “P” refers to the treatment plan, treatment simulation, and treatment strategies that are derived following a complete diagnosis. A treatment blueprint may also be developed. Inform “I” refers to informing the patient and involved health professionals concerning the diagnosis, treatment options, treatment plan, risk assessment, and potential benefits. Perform “P” refers to treatment following a precise “blueprint” that may implement a treatment guide based upon the planning information.

In addition, software has been developed to work with 3-D imaging that can fabricate models, surgical stints, and even restorations, further improving outcomes and reducing risks.

### *Legal Consequences*

Informed consent may not be a defense in cases where a dental implant contacts a nerve or penetrates the sinus cavity, or where orthodontic treatment is stalled due to a mesioden not visible on standard imaging, or where the roots of an impacted asymptomatic tooth can't be visualized.

If CBCT 3-D imaging was not offered to the patient in such cases, the patient may have a claim that they would have agreed to such imaging had it been offered, and in litigation will be able to produce expert witnesses who will state that the injury at issue could have been avoided with use of such imaging. The additional data that 3-D imaging provides, allows for adjustments to the treatment plan and implementation so as to avoid many complications. Therefore, the standard of care by definition requires that, in such cases, patients be offered the option of 3-D imaging, and, if they decline after being informed of the risks, benefits, and alternatives, then informed refusal should be obtained and documented.

### *Tips*

#### *Orthodontics*

In cases of full-mouth orthodontics, the offer of CBCT 3-D imaging has become a standard of care in order to better visualize the location of the roots in the bone, any hidden structures, and the precise position of impacted teeth to other structures, such as root proximity. There is also a better appreciation of the structure and quality of the bone in which the teeth will be moving.

#### *Extractions*

Where conventional imaging suggests that roots of teeth to be removed might be near vital structures like nerve and sinus cavities, CBCT 3-D would provide a better risk analysis of the potential complication. Accordingly, the

standard of care requires that patient be offered that option, and, if they decline, informed refusal would include a discussion of increased risks of complications.

More importantly, the CBCT imaging would provide the doctor, and, therefore the patient, with better information as to the likelihood of nerve injury or sinus communication.

### Implants

One of the fastest growing areas of dentistry is the placement of dental implants. Unfortunately, there has been a concurrent raise in claims and suits involving dental implants, mostly associated with nerve damage and sinus perforation, in addition to failure associated with poor alignment.

Accordingly, if placement of an implant might approach a nerve, invade the sinus, or penetrate out of the confines of the jawbone, the patient should be offered a discussion of CBCT 3-D imaging. If the patient refuses, the doctor should obtain and document that an informed refusal discussion took place. In addition, CBCT 3-D patients should be advised of the risks, benefits, and alternatives to such treatment, based upon any additional data provided by the imaging.

It is noteworthy that in the experience of the authors in the last three years, when patients have experienced significant complications with the placement of implants — such that they sought another expert's opinion or legal counsel — the first thing that happened is that they were sent for CBCT imaging. The results of such studies are often the determining factor as to whether or not a claim is made or a suit is filed.

### Summary

The evolution of CBCT 3-D imaging has dramatically changed the potential for presurgical and pretreatment planning

such that outcomes are more predictable and complications more avoidable. Treatment paths in orthodontics, proximity of vital structures in surgical extraction and implant placement, and 360-degree root morphology for endodontics are all better appreciated with 3-D imaging.

Accordingly, with the increasing availability of such systems, the standard of care has been elevated such that 3-D imaging should be part of the patient discussion of options when planning orthodontics, implant placement, surgical extractions, and difficult orthodontics. The prudent practitioner will discuss the risks, benefits, and alternatives to these options, and if the patient declines the ideal recommended treatment, the dentist will obtain and document the informed refusal. The result will be improved outcomes, increased patient satisfaction, and effective risk management of potential claims. ■ ■ ■ ■ ■

### REFERENCES

1. Quintero JC, Trosien A, et al, Craniofacial imaging in orthodontics: historical perspective, current status and future developments. *Angle Orthod* 69(6): 491-506, December 1999.
2. Stratemann SA, Huang JC, et al, Comparison of cone beam computed tomography imaging with physical measures. *Dentomaxillofac Radiol* 37(2):80-93, February 2008.
3. *Landeros v. Flood* 17 Cal3d 399, 1976.
4. California Business and Professions Code 1670.
5. *Alef v. Alta Bates Hospital* 8 Cal 2d 82, 1952.
6. *Williams v. Volkswagenwerk* 180 CA3d 1244, 1986.
7. California Evidence Code 721.
8. [http://www.fpamed.com/forensic\\_psychiatry/kellyfrye\\_and\\_daubert](http://www.fpamed.com/forensic_psychiatry/kellyfrye_and_daubert). Accessed June 24, 2009.
9. *Moore v. Preventive Medicine Medical Group, Inc.* 178 CA 3d 728, 1986.
10. *Truman v. Thomas*, 27 C3d 285, 1980.
11. [http://www.livescience.com/history/george\\_teeth\\_050126.html](http://www.livescience.com/history/george_teeth_050126.html) Accessed June 24, 2009.
12. *Cobbs v. Grant*. 8 Cal3d 229, 1972.
13. *Wickline v. State of California* 192 CA 3rd 1542, 1986.
14. <http://www.justia.com/trials-litigation/docs/caci/500/534.html> Accessed June 24, 2009.
15. Burstein J, Mastin C, Le B. Avoiding injury to the inferior alveolar nerve by routine use of intraoperative radiographs during implant placement. *J Oral Implantol* 34(1):34-8.
16. Yikontiola L, Moberg K, et al, Comparison of three radiographic methods used to locate the mandibular canal in the buccolingual direction before bilateral sagittal splint osteotomy. *Oral Surg Oral Med Oral Pathol Oral Radiol Endod* 93:736-42, 2002.
17. Pawelzik J, Cohnen M, et al, A comparison of conventional panoramic radiographs with volumetric computed tomography images in the preoperative assessment of impacted mandibular third molars. *J Oral Maxillofac Surg* 60:979-84, 2002.
18. Peck JL, Sameshima GT, et al, Mesiodistal root angulation using panoramic and cone beam CT. *Angle Orthod* 77(2):206-13, March 2007.
19. Adams GL, Gansky SA, et al, Comparison between traditional 2-dimensional cephalometry and a 3-dimensional approach on human dry skulls. *Am J Orthod Dentofacial Orthop* 126(4):397-409, October 2004.
20. Miller AJ, Maki K, Hatcher DC, New diagnostic tools in orthodontics. *Am J Orthod Dentofacial Orthop* 126(4):395-6, October 2004.
21. Mah J, Hatcher D, Three-dimensional craniofacial imaging. *Am J Orthod Dentofacial Orthop* 126(3): 308-9, October 2004.
22. Hatcher D, CBCT (3-D imaging): application for selected articular disorders and associated facial growth. In: McNamara JA Jr, Kapila SD, eds. Temporomandibular disorders and orofacial pain: separating controversy from consensus. Monograph 46, Craniofacial Growth Series, Department of Orthodontics and Pediatric Dentistry and Center for Human Growth and Development, The University of Michigan, Ann Arbor, pages 125-45, 2009.
23. Hatcher D, Diagnostic imaging, reconstructive preprosthetic and maxillofacial surgery, second ed., Fonseca R, Davis H, W.B. Saunders Company, 1995.
24. Hatcher DC, Dial C, Mayorga C, Cone beam CT for presurgical assessment of implant sites. *J Calif Dental Assoc* 31(11):825-33, November 2003.
25. Schropp L, Wenzel A, Kostopoulos L, Impact of conventional tomography on prediction of the appropriate implant size. *Oral Surg Oral Med Oral Pathol Oral Radiol Endod* 92:458-63, 2001.
26. Gaggi A, Schultes G, Karcher H, Navigational precision of drilling tools preventing damage to the mandibular canal. *J Craniomaxillofac Surg* 29:271-5, 2001.
27. Siebegg M, Schneider BT, et al, Use of an image-guided navigation system in dental implant surgery in anatomically complex operation sites. *J Craniomaxillofac Surg* 29:276-81, 2001.
28. Almg DM, Torrado E, Meitner SW, Fabrication of imaging and surgical guides for dental implants. *J Prosthet Dent* 85:504-8, 2001.
29. Mah JK, Danforth RA, et al, Radiation absorbed in maxillofacial imaging with a new dental computed tomography device. *Oral Surg Oral Med Oral Pathol Oral Radiol Endod* 96(4):508-13, October 2003.

### TO REQUEST A PRINTED COPY OF THIS ARTICLE, PLEASE

CONTACT Arthur Curley, Bradley, Curley, Asiano, Barrabee & Gale PC, 1100 Larkspur Landing, Suite 200, Larkspur, Calif., 94939.